

# The Bonded Functional Esthetic Prototype: Part 2

A patient-friendly pretreatment restoration with excellent esthetic results

Edward A. McLaren, DDS, MDC

**P**art 1 of this two-part series discussed the rationale and development of the Bonded Functional Esthetic Prototype (BFEP). This pretreatment restoration (formerly called a mock-up, long-term provisional, or temporary) enables fabrication of 14 teeth from composite in 1 hour. It also allows patients to preview their ultimate restorative treatment while simultaneously providing a solution until further treatment can be completed.

This article elaborates on the clinical and chairside technical steps necessary to create functional and esthetic BFEPs.

and treating the case (Figure 1). An occlusal analysis should be performed initially using a semi-adjustable articulator, which is recommended because it facilitates adjustments to the plane of occlusion and vertical dimension of occlusion. A facebow record should be taken and transferred, along with jaw registration mounting, especially if the patient's vertical dimension must be altered.

### Impressions

Detailed impressions are made and, crucial to the success of the BFEP, should demonstrate ideal interproximal and gingival margin detail without voids or air bubbles. When

an impression is free of defects and highly detailed, the matrix will fit the teeth tightly and the composite will adapt well to the tooth surfaces. If a proper impression is taken and the matrix fits well, the BFEP will only need minimal finishing after placement.

Then, prior to creating the 2-dimensional (2D) smile design, stone casts are created from the preoperative impressions and a caliper used to measure the height of the maxillary central incisors (Figure 2).

### Smile Design

The concept and utilization of digital smile design has become common practice in many dental offices and can be completed without the use of challenging or expensive equipment. Instead, the author begins with a cost-effective and user-friendly 2D digital editing software (Photoshop CS5, Adobe Systems Incorporated, www.adobe.com) in a technique called Photoshop Smile Design.

Various photographic editing tools provided with the software (ie, Clone, Liquefy, Dodge, Grids) enable the operator to move and graft

### Diagnostics

With the exception of correcting or repairing previous restorative work, diagnostic information should be collected prior to designing



**EDWARD A. MCLAREN,**  
DDS, MDC

Clinical Professor  
Founder and Director  
UCLA Post Graduate Esthetics

Director  
UCLA Center for Esthetic Dentistry

Founder and Director  
UCLA Master Dental  
Cerapist Program  
UCLA School of Dentistry  
Los Angeles, California

Private Practice limited to  
Prosthodontics and  
Esthetics Dentistry  
Los Angeles, California

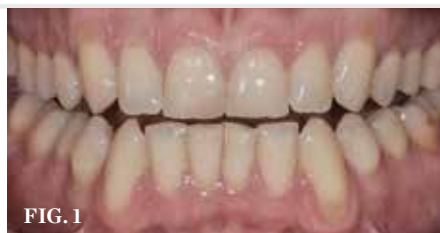

FIG. 1



FIG. 2

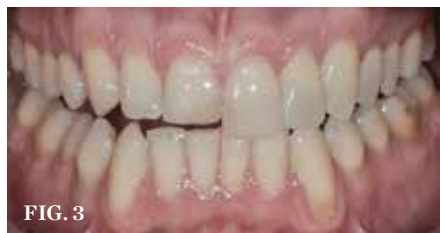

FIG. 3

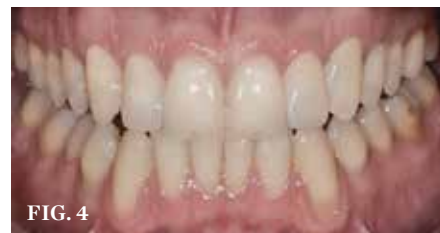

FIG. 4

**PRELIMINARY STEPS (1.)** Close-up preoperative view demonstrating wear, improper inclination, and other esthetic issues. **(2.)** Stone models were made from the preoperative impressions and calipers used to measure vertical height of the maxillary central incisors. **(3.)** Digital smile design techniques were used to help the patient visualize proposed improvements. **(4.)** Photoshop applications were used to demonstrate how bleaching would change the appearance of the patient's smile.

sections of tooth structure, close spaces, adjust the smile line, and bleach the teeth within the image (Figure 3 and Figure 4). It must be made clear to the patient that the altered photographic image does not represent the definitive treatment results. However, it does allow the patient to preview how treatment may appear.

### Design Wax-Up

After completing the 2D smile design and obtaining patient approval of the treatment plan, the case is created in a 3-dimensional design wax-up (Figure 5). Although commonly referred to as a diagnostic wax-up, the author prefers the terms “design wax-up” or “treatment plan wax-up” because nothing is being diagnosed, but simply designed. By describing the wax-up this way, patients have a better understanding of its purpose.

### Carrier Tray Fabrication

The design wax-up serves as a foundation for fabricating a custom hard tray by placing a 2-mm spacer of laboratory putty (COE, GC America, www.gcamerica.com) on the design model and using a colorless and translucent urethane dimethacrylate-based material (Triad® TranSheet™ colorless, DENTSPLY International, www.dentsply.com) (Figure 6 and Figure 7). The custom tray is then cured in a specialized light-curing unit (Triad) with a tungsten halogen light source (Figure 8).

### Matrix Fabrication

The matrix used for BFEP fabrication is then made by first spraying the design model with a thin layer of silicone as a separator. A clear vinyl polysiloxane (VPS) material (eg, Tescera™, BISCO Inc., www.bisco.com; Star

VPS, Danville, www.danvillematerials.com) is placed into the tray and onto the design model (Figure 9 and Figure 10). With the tray seated securely on the design model, excess VPS material is trimmed (Figure 11). When the matrix is complete, it should provide great detail and allow the composite to adapt well to the teeth. When the patient returns to the office for placement of the BFEP, the matrix should be tried in to ensure a proper fit (Figure 12). To save time, the dentist may have the trays, wax-up, and matrix made by the laboratory.

### Preparation

Unlike other esthetic restorative techniques, using the BFEP requires very little to no tooth preparation (ie, nearly immeasurable amount of tooth structure lost). Although the enamel of the teeth receiving treatment must be etched,

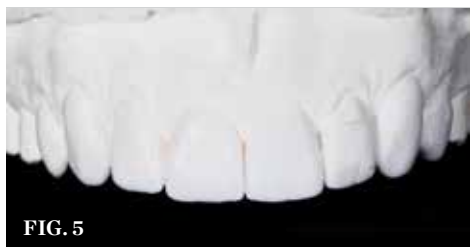

FIG. 5

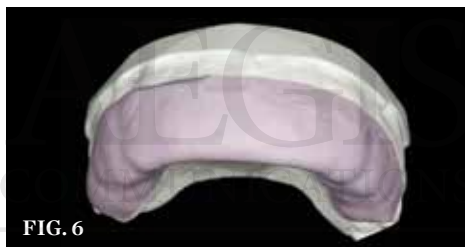

FIG. 6



FIG. 7



FIG. 8

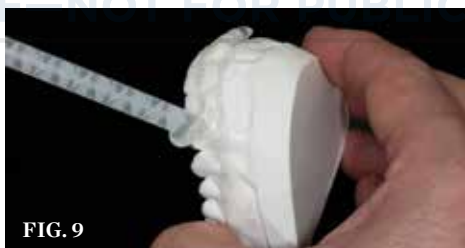

FIG. 9

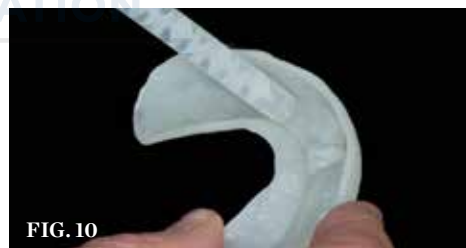

FIG. 10



FIG. 11

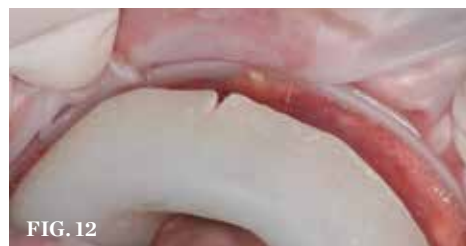

FIG. 12

**BFEP CREATION (5.)** An enhanced design wax-up model was created to demonstrate improved tooth length and inclination. **(6.)** To begin fabricating the bonded functional esthetic prototype (BFEP), a 2-mm thick spacer of lab putty (or base wax) is placed on the design wax-up model. **(7.)** To create the hard tray, a clear tray material is placed over the putty. **(8.)** The custom tray is cured in a specialized light-curing unit. **(9 AND 10.)** Clear vinyl polysiloxane (VPS) material is placed into the tray and onto the design model. **(11.)** With the design model seated securely into the hard tray, excess VPS material is trimmed and removed. **(12.)** At the BFEP appointment, the matrix is tried in the mouth to verify complete seating.

the procedure is almost reversible. Many are hesitant to call a treatment reversible, because even with the BFEP, enamel is still lost during the etching process, and if removed, slight amounts of tooth structure will inevitably be lost. This treatment is closer to reversible than any other prior treatment, however.

### Etching Pattern

Once a definitive BFEP material (ie, composite or bis-acryl) has been selected based on the aforementioned requirements, an etching pattern is then selected that will achieve the best temporary bond. Like BFEP material selection, the etch pattern is selected based on the length of time the BFEP is expected to function.

In cases in which the prototype will remain in use for only a few weeks (to a maximum of 8 weeks), only 3 mm of spot-etching should be completed on the facial surface of the teeth (Figure 13). When spot-etching this type of case, it is important to prevent etching near the interproximal margins and incisal edges. Eliminating the need to remove excess composite materials on these areas simplifies finishing and polishing.

When the BFEP will function longer (eg, 8 weeks to 6 months), a larger etch pattern is required to prevent chipping, breaking, leaking, and dislodging, because more stress will be placed on the bonded surfaces.<sup>1,2</sup> The full-facial etch pattern just short of the gingival margins and proximal contacts<sup>3,4</sup> is most commonly used. It is critical to remain short of the gingival margins because when the very thin composite finish line is placed, it will be very difficult to see, even under magnification. As a result, when the BFEP is removed during normal preparation for veneer placement, it will be much easier to remove the composite in these regions. In addition, if the composite is not removed during preparation, it may come off during classic temporary removal at the cement appointment, leaving a void at the margins that may affect the fit of the final.

Further, depending on the coverage necessary, the incisal edge may also require etching on the lingual.<sup>1,5</sup> For example, when only lengthening by 1 mm, often a small slot is placed on the incisal edge to help prevent BFEP fracture during function. When restoring the lingual, the same

protocol is followed (ie, 2-mm to 3-mm spot-etch and avoid the margins).

Occasionally, a full-etch pattern is done on every area of the tooth to receive composite. Cases that will be in the mouth for longer than 6 months for whatever reason should be fully etched and bonded to prevent microleakage and recurrent caries. This technique will make it more difficult to finish removal of composite at the preparation appointment.

### Bonding Pattern Selection

Patient compliance with home care instructions and length of function of the BFEP are considerations when selecting an appropriate bonding pattern for applying the recommended fifth-generation bonding agent (All-Bond, BISCO, Inc.). The bonding agent is first placed on the etched tooth and cured separately from the composite (Figure 14). Then the composite may be placed in the matrix and over the prepared teeth.

When the dentist is concerned with patient compliance and maintaining appointments, the fifth-generation bonding agent is placed on all tooth surfaces receiving BFEP treatment,

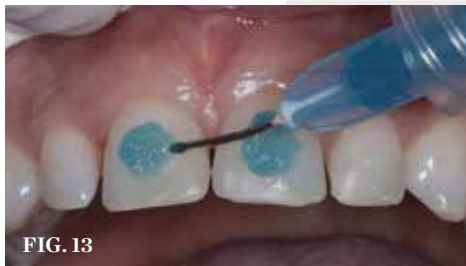

FIG. 13

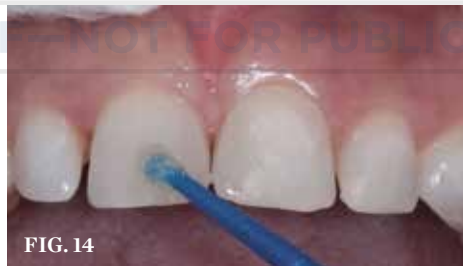

FIG. 14

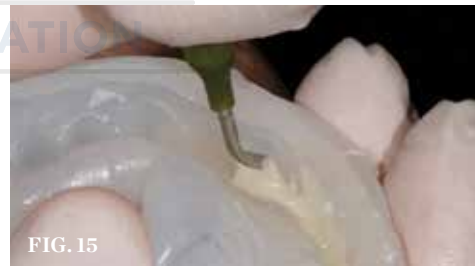

FIG. 15

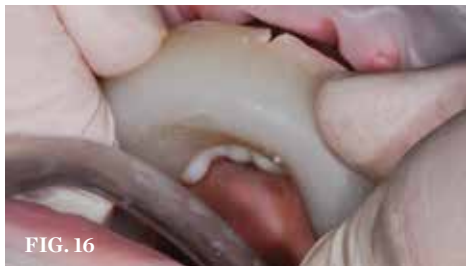

FIG. 16

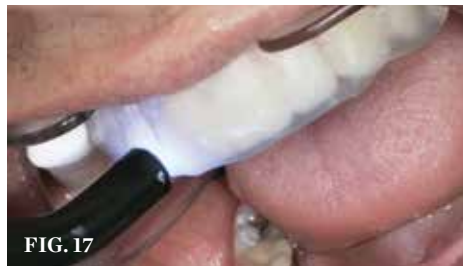

FIG. 17

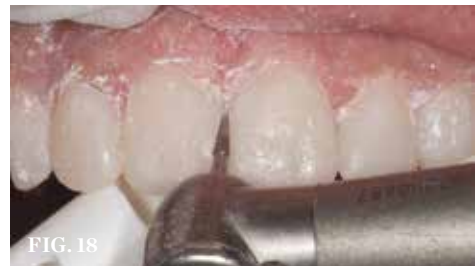

FIG. 18

**FINALIZING THE BFEP (13.)** Following conservative tooth preparation, the facial surface of the teeth is etched, taking care to remain 0.5 mm away from the free gingival and interproximal margins. **(14.)** A fifth-generation adhesive bonding agent is applied to the entire surface of the preparations to ensure a complete seal and cured. **(15.)** Reveal™ is placed into the matrix, with care taken to ensure complete and precise coverage of all tooth areas. **(16.)** The BFEP matrix, fully loaded with composite, is seated onto the preparations and held securely in place. **(17.)** With the clear VPS matrix still in place in the mouth, the BFEP restorations are cured from posterior to anterior. **(18.)** A carbide bur is used to refine the interproximal margins and open the embrasures.

including areas that were not etched. This bonding pattern is preferred because it provides some sealing and enhances retention, even when the teeth have only undergone a 3-mm to 4-mm etch.<sup>1,5</sup> In the author's experience, an acceptable short-term bond is still achievable in areas that have not been etched.

If the dentist is convinced that the patient will follow the treatment and appointment schedule, however, the bonding agent may be restricted to only etched tooth surfaces; this ensures easy and swift removal of the prototype when the final restorations are placed.

### Seating

Prior to placing the tray and matrix intraorally, the dentist should ensure that the two could be easily separated, which is essential for complete curing of the BFEP composite. Because the tray and matrix are both 2 mm thick, curing is more difficult and time consuming if they cannot be separated. Additionally, when the tray and matrix are separated, the dentist can better view the BFEP and ensure complete coverage and seating.

Reveal™ (BISCO, Inc.) is placed in the matrix that is carried in the hard tray and then seated

intraorally (Figure 15 and Figure 16). After the composite is allowed to flow, the hard tray is removed and the loaded matrix remains on the teeth. At this time, the matrix is evaluated to ensure complete seating. If the matrix is not completely seated, the hard tray is repositioned onto the matrix and pressure applied again.

After determining that the matrix is seated properly, the BFEP is cured through the matrix (Figure 17); if the matrix encompasses molars, light curing should begin at the posterior, where it tends to be more challenging to control saliva. To further prevent contamination of the posterior composite, cotton rolls, dry angles, and the saliva ejector have proved useful. Specialized curing lights may also be used, which provide retraction and suction when curing (Isodry/Isolite™, Isolite Systems, www.isolitesystems.com) to expedite this process. These tools may only be used when curing one quadrant at a time, however, per manufacturer's instructions.

When learning the technique, the dentist may opt to only do one quadrant at a time, or the posterior followed by the anterior. The technique becomes much easier to complete once it is learned. The author now enlists the

help of his staff, for example, with one person applying the bonding agent while another dries and cures, after which another staff member places the tray.

### Finishing and Polishing

With the BFEP bonded in place, finishing and polishing become predictable tasks, providing the impressions were free of voids and the definitive matrix fit well. In some cases, the composite may appear slightly underfilled or overfilled. When underfilled, there may be a void at a margin that can be easily corrected by flowing more of the same composite into the void, then curing. When overfilled, the flange will require simple trimming or adjustment with a carbide or diamond bur, providing the BFEP fits tightly. However, if the BFEP appears grossly underfilled or overfilled, the case may need to be redone, because composite will either dislodge or appear very porous.

After evaluating the fit of the BFEP, trim any small amount of flash on the margins and open the embrasures with a carbide or diamond bur. For this process, 12-fluted red-stripe ET carbide burs are recommended, because these will not cut through tooth structure.<sup>6</sup> Additionally, red-stripe ET carbide burs work well on composite.<sup>6</sup> If the composite is too thick, however, red-stripe ET diamonds are more effective.<sup>6</sup> Only use red-stripe burs/diamonds for this process; white and yellow have been found to be ineffective for this technique.

After removing the flash, slightly open the interproximal using a serrated cutting instrument (eg, Cerisaw™, DenMat, www.denmat.com; IPR Strips, ContacEZ, www.contacez.com). The interproximal should be opened only enough to allow the patient to use a floss threader.

Because the BFEP is basically a 14-unit splint, the dentist must decide whether to separate the teeth. Separating each individual tooth can only be accomplished during the matrix design stage of fabrication, however.

After trimming and opening the interproximal spaces (Figure 18), occlusal adjustments are completed using the articulating paper, bite down, and protrude technique. If any occlusal or protrusive adjustments are necessary, a fine diamond is used.<sup>6</sup> Once occlusal and protrusive

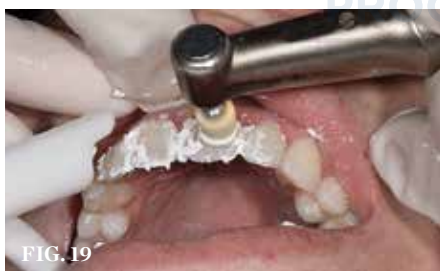

FIG. 19

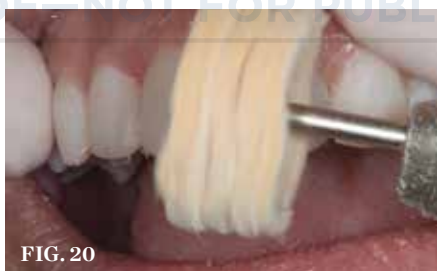

FIG. 20

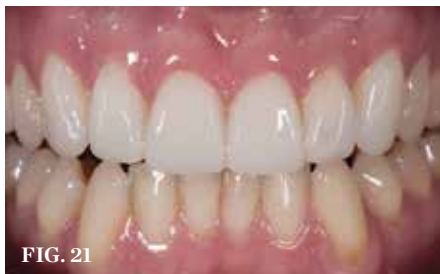

FIG. 21

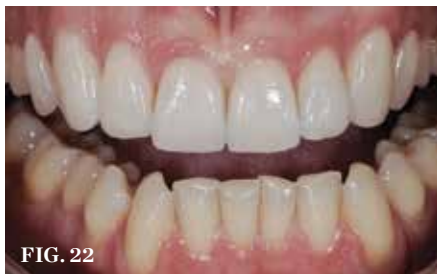

FIG. 22

**FINISHING AND POLISHING TECHNIQUE (19.)** Polishing paste and felt cups are used to polish the facial surface of the BFEP composite restorations. **(20.)** A leather buff and polishing paste complete the BFEP restorations. **(21.)** Close-up view of the patient's BFEP restorations. **(22.)** Close-up view of the patient's final restorations.

adjustments have been made, final finishing and polishing can be completed.

### *Definitive Finishing and Polishing Technique*

To impart a natural and lifelike appearance to the BFEP, a silicone point (Enhance<sup>®</sup>, DENTSPLY Caulk, [www.caulk.com](http://www.caulk.com)) is quickly grazed over the surface of the composite.<sup>6</sup> Water should be used at this point to prevent scorching.<sup>6</sup> The composite is then gone over quickly with the diamond-impregnated point (PoGo<sup>®</sup>, Dentsply Caulk).<sup>23</sup> Polishing paste (Enhance) is placed on the same point, and the composite is polished.

Once a satisfactory polish is achieved, the process is repeated with a felt cup or felt point (FlexiCups/FlexiPoints, Cosmedent, [www.cosmedent.com](http://www.cosmedent.com)) and the same polishing paste to give the BFEP even more luster (Figure

19).<sup>6</sup> Final polishing is then completed with a leather buff (Brasseler USA, [www.brasselerusa.com](http://www.brasselerusa.com)) and polishing paste to enhance the gloss (Figure 20). Further, if the dentist would like to bring the final polish to the line angle, leather buffs designed for laboratory use have proven useful. However, the buffs are particularly large and can only be used to the first bicuspid.

Overall, the entire finishing and polishing technique should take only 2 to 5 minutes per tooth. Further, when finished, the composite BFEP should display a pleasing luster, polish, and the esthetics required to meet the needs of the patient until the definitive treatment can be completed (Figure 21).<sup>6</sup> Figure 22 demonstrates the final restorations after cementation.

### **Discussion**

An invaluable tool, BFEP can make patients truly happy with the appearance of their teeth

after treatment, and they often receive many compliments from friends and family members. These compliments often improve patient compliance and motivate patients to undergo final treatment sooner.<sup>7</sup> Additionally, when the dentist removes the BFEP for definitive treatment with porcelain or other materials, preparation is simpler because the shape of the teeth has already been worked out.

Although the BFEP is a simplified treatment to satisfy immediate needs, a certain skill set is required and, therefore, dentists should not provide full-arch treatment initially. Instead, they should begin with relatively straightforward cases that require only four to six provisionals to gain experience in fabricating proper BFEPs. During this time, it may also be beneficial to complete all restorative dentistry cases in composite to understand the form, function, and esthetics of the different materials

# AEGIS

## Implacare<sup>®</sup> II: THE WAY TO GO FROM THE ONES WHO KNOW

COMMON SENSE

### PROOF—NOT FOR PUBLICATION



Two dental instruments with thin, curved tips are shown on the left. In the center is a diagram of a tooth with a grid overlay, and on the right is a 3D model of a tooth with a thin, curved tip being applied to its surface.

**YOUR PATH TO IMPLANT MAINTENANCE**

Hu-Friedy's latest development in implant maintenance, Implacare II, provides thinner working ends and new designs so you have the choices you need for the best adaptation and efficiency. More importantly, since Implacare II is made from Plasteel, a high-grade, unfilled resin, it will cause the least amount of alteration to implant abutment surfaces.\*

**PERIODONTAL**



> PLASTEEL<sup>®</sup>> 20% THINNER TIP DESIGNS> 5 TIP OPTIONS

Visit us online at [Hu-Friedy.com](http://Hu-Friedy.com)

How the best perform



©2013 Hu-Friedy Mfg. Co., LLC. All rights reserved.\*Data on file.

(Circle 66 on Reader Service Card)

available. This will enable dentists to base their BFEP material decisions on the shape, strength, and esthetics required of each case.

After two or three cases, working only back to the bicusps, the dentist may feel sufficiently comfortable to treat more complex cases. Eventually, after mastering the BFEP concept, dentists can provide their patients with flexible options that incorporate BFEPs for 14 teeth in 1 hour.

**Conclusion**

Although dentists want to provide complete dentistry and understand what that often requires, there is still a cognitive dissonance with patients who demand the best in treatment in the shortest time, and for the lowest cost.<sup>89</sup> Providing a solution to this problem, the BFEP allows dentists to provide complete dentistry, but on the patient's terms. Although the author

prefers to work in porcelain, the BFEP allows the best in function, stability, and esthetics in the interim, all while spreading the cost of definitive treatment over time to reduce the initial economic impact to the patient.<sup>10</sup>

**Disclaimer**

The author did not receive any financial compensation/royalties from any manufacturers of any products used or discussed in this article.

**References**

1. Hobson RS, McCabe JF, Rugg-Gunn AJ. The relationship between acid-etch patterns and bond survival in vivo. *Am J Orthod Dentofacial Orthop.* 2002;121(5):502-509.
2. Jefferies SR. The art and science of abrasive finishing and polishing in restorative dentistry. *Dent Clin North Am.* 1998;42(4):613-627.
3. Hervas-Garcia A, Martinez-Lozano MA, Cabanes-Vila J, et al. Composite resins. A review of the materials

and clinical indications. *Med Oral Patol Cir Bucal.* 2006;11(2):E215-E220.

4. Barghi N. To silanate or not to silanate: making a clinical decision. *Compend Contin Educ Dent.* 2000;21(8):659-662, 664.

5. Lopes GC, Thys DG, Klaus P, et al. Enamel acid etching: a review. *Compend Contin Educ Dent.* 2007;28(1):18-24.

6. Jefferies SR. Abrasive finishing and polishing in restorative dentistry: a state-of-the-art review. *Dent Clin North Am.* 2007;51(2):379-397, ix.

7. Becker MH, Maiman LA. Sociobehavioral determinants of compliance with health and medical care recommendations. *Med Care.* 1975;13(1):10-24.

8. Junnila T. Growing your practice in a down economy. *Northwest Dent.* 2010;89(3):49-51.

9. Levin RP. How dentistry weathers a slow economy. *J Am Dent Assoc.* 2007;138(3):391-392.


10. McLaren EA, LeSage BP. Feldspathic veneers: what are their indications. *Compend Contin Educ Dent.* 2011;32(3):44-49.

**HI-TEC IMPLANTS**



**Zirconium Abutments**  
**MAY SPECIAL!**  
**\$69**  
 ☎ 800-452-0582

**IMPLANTS**  
 including cover screw  
**\$79**  
 ☎ 800-452-0582



**IMPLEX**  
 Internal Taper & Hex

**HI-TEC IMPLANTS LTD** Visit our Website: [www.hitec-implants.com](http://www.hitec-implants.com)

USA Office: Tel: 800-452-0582 e-mail: [usa@hitec-implants.com](mailto:usa@hitec-implants.com)  
 Head Office: Tel: +972-9-9587775 e-mail: [sales@hitec-implants.com](mailto:sales@hitec-implants.com)

(Circle 67 on Reader Service Card)