



CONSIDERATIONS IN THE USE OF POLYMER AND FIBER-BASED INDIRECT RESTORATIVE MATERIALS

Edward A. McLaren, DDS*
Robert Rifkin, DDS†
Vincent Devaud, MDT‡

Restorative materials and techniques are constantly refined in order to address the aesthetic expectations of patients. Second-generation laboratory-fabricated composite materials have recently been developed to combine the advantages of porcelain with composite resin. This class of biomaterial can be utilized in a variety of direct and indirect clinical applications that include inlay/onlay restorations, full-coverage crowns, fixed partial dentures, and implant-supported prostheses. This article reviews considerations for the use of these materials from clinical indications through cementation.

Key Words: polymer, optimized composite, fiber reinforced

Due to the exponentially increasing demand of patients for improved aesthetics, novel materials and restorative techniques are continually being developed.¹ Concern over the limitations of ceramics (ie, abrasiveness, brittleness, reparability, and technique-sensitivity) has resulted in the increased use of polymer-based restoratives for direct and indirect applications.² Difficulties associated with polymer-based systems have been wear resistance, maintenance of polish, and staining due to high water sorption.² Improvements in resin technology and polymerization methods have enabled the development of optimized resin and fiber-based restorative materials.³

Several materials that have been termed "polyglass" or "ceromer" (ceramic optimized polymer) have recently been developed.² This class of materials is reported to possess the advantages of porcelains and composite resin materials without having their limitations. Examination of the components of these new materials reveals that they are composed of a resin matrix with an inorganic ceramic filler, as were previous composite systems. One report has defined polyglass and/or ceromers as an "improved composite with increased cross linking, and increased degree of polymerization."⁴ While the definition of a composite is a material with two or more phases, ceromers or polyglasses are clearly composites that have had their physical properties optimized. The improved physical properties are due to higher filler loading and the inclusion of multifunctional monomers that have more reaction (bonding) sites, which increase the cross-linking between the polymeric chains.⁵ In addition, the increased degrees of polymerization due to heat, pressure, and nitrogen curing improve strength and wear characteristics.^{3,5}



Figure 1A. Facet of a polymer-based enamel material (belleGlass, Kerr/Sybron, Orange, CA). 1B. Facet of a natural tooth. Note the similar opalescent effect.

*Director, UCLA Center for Esthetic Dentistry; Lecturer, Graduate Prosthodontics, UCLA School of Dentistry, Los Angeles, California; Adjunct Assistant Professor, University of Oregon School of Dentistry, Portland, Oregon; private practice, Monarch Beach, California.

†Private practice, Beverly Hills, California.

‡Dental technician, Devaud Laboratories, Pasadena, California.

Edward A. McLaren, DDS
32241 Crown Valley Parkway, Ste. 240
Monarch Beach, CA 92629

Tel: 949-488-2787

Fax: 949-493-2057

One development associated with the creation of optimized composites is the use of fiber reinforcement to enhance physical properties. Fibers have been recently used as a coping framework onto which the optimized composites can be veneered. These fiber-reinforced materials exhibit significantly increased physical properties over nonreinforced materials, and possess values that approach those of metal-reinforced ceramics.^{6,7} As compared to opaque metal substances, the translucent fibers are more easily matched to the natural dentition. This article discusses considerations for the use of optimized composite materials from clinical indications through cementation. It also highlights an optimized composite that can be fiber reinforced or used as a veneering material on castable and alternate dental alloys.

Optimized Composites: Material Properties

One polymer-based indirect restorative material (belleGlass, Kerr/Sybron, Orange, CA) has a resin matrix that contains a mixture of aliphatic and urethane dimethacrylate resins, which is similar to contemporary resin technology. The filler particles are bariumaluminosilicate glass of different size in the opacous dentin and dentin materials. The enamel materials are unique in that the filler particles are primarily borosilicate glass of 0.4 μm to 0.6 μm particle size,^{2,5} which imparts optical properties (eg, translucency, opalescence) similar to those of natural teeth (Figure 1). The fine particle size of the enamel materials allows for improved polishability. The materials are dual cured; they are first built up, sculpted, and then polymerized. Incremental additions of composite are applied until the final contour is achieved. One of the primary benefits of these materials is that the color and effects can be observed during fabrication (Figure 2), while ceramics cannot be viewed until firing. The final curing is completed at 135°C and a pressure of 60 psi in a nitrogen atmosphere that eliminates internal and external oxygen.³ The elimination of air bubbles allows for a more complete cure, as no air-inhibited layer remains uncured. The degree of polymerization by this method has been reported to be 99% with a concomitant increase in hardness that correlates to increased wear resistance.^{8,9} In a 5-year study, the wear rate of belleGlass materials was noted to be less than 1.5 μm per year.² No incidences of fracture, caries, or marginal breakdown were observed, and a subjective assessment reported no observable loss of surface luster (polish).

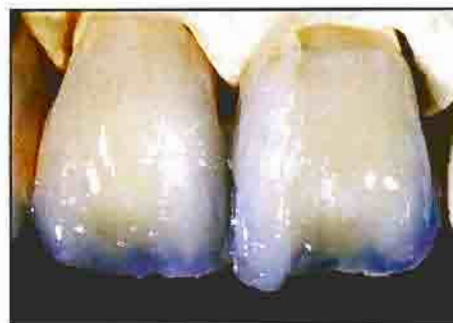

Figure 2. Incremental buildup of veneering composite; 3-dimensional color effects can be observed while the material is being layered.

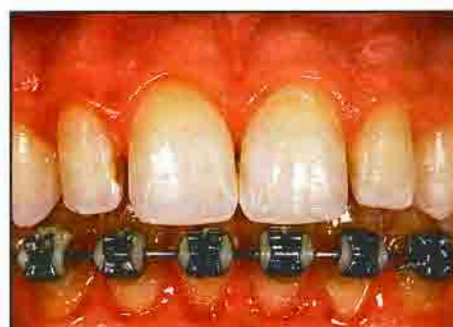

Figure 3. Preoperative view of a patient following completion of orthodontic therapy. Note the presence of pegged lateral incisors with concomitant diastemata.

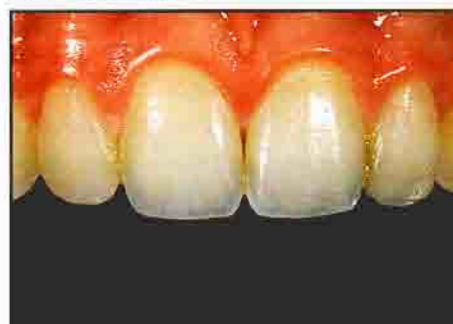

Figure 4. Postoperative view of the patient following diastemata closure with direct composite resin (Herculite XRV, Kerr/Sybron, Orange, CA).

Selection Criteria:

Direct vs. Indirect Restorations

One primary objective of restorative dentistry is the preservation of sound tooth structure. The principal benefit provided by adhesive tooth-colored restorations — other than aesthetics — is the conservative restoration of teeth. For small- to medium-sized restorations that are subject to minimal stresses and where peripheral enamel remains, direct composite resins have achieved excellent clinical success.¹⁰

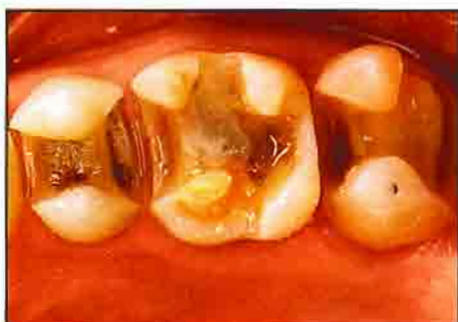

Figure 5. Occlusal view of inlay and onlay preparations with butt joint margins.

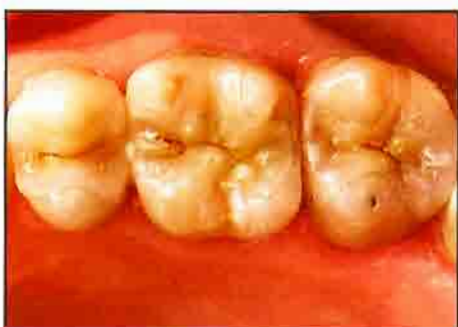

Figure 6. Inlay and onlay restorations are seated in the preparations. Note the visible margins prior to adhesive luting.

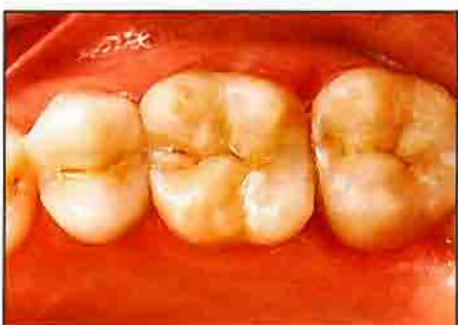

Figure 7. Postoperative occlusal view of inlay and onlay restorations with margins that are virtually imperceptible (Laboratory procedure: Vincent Devaud, MDT).

Due to the inherent material properties of composite resins, larger restorations are indicated for an indirect fabrication technique.¹¹ Despite significant compositional improvement, direct polymer-based restorations continue to exhibit a significant degree of polymerization shrinkage that can contribute to microgap formation.¹¹ Direct or light curing of composite is characterized by a significantly reduced degree of conversion (polymerization) compared to heat/pressure and nitrogen curing,^{3,5,8} which can result in poor wear resistance. Increased curing periods have

demonstrated a significant increase in wear resistance and decreased water sorption.⁵ The development of proper interproximal contacts and occlusal anatomy remains a technique-sensitive procedure with direct composite restorations. Indirect restorations address many of the inherent challenges that have been associated with directly fabricated composite restorations. Thus, for medium to large restorations or when multiple restorations are planned (particularly in posterior teeth) indirect heat, pressure, and nitrogen-cured restorations should be planned. Several clinical studies have demonstrated a highly significant improvement in clinical performance for indirect restorations.^{12,14}

It is time consuming to complete a medium to large direct composite restoration with a high degree of clinical excellence and, due to the physical limitations of direct composite materials, the quality of the result is questionable. Indirect restorations benefit from improved curing procedures and can be layered and sculpted to ideal anatomic and optical form. When the chairtime required to fabricate a direct composite restoration would exceed the preparation and subsequent cementation of an indirect restoration, it is prudent to perform the indirect restoration. Direct procedures can be ideally performed on areas that necessitate minimal preparation (eg, anterior diastema) (Figures 3 and 4).

Inlay, Onlay, and Veneer Considerations

The primary indications for the use of this class of materials are inlay and onlay restorations, as one 5-year clinical study has demonstrated 100% success with such materials.³ Preparations for adhesive inlay/onlay restorations consist of rounded internal line angles with divergent walls (no undercuts), sharp cavosurface margins, and the allowance for a 1.5 mm thickness of material occlusogingivally and buccolingually.¹⁵ The literature contains a variety of recommended finish lines that includes bevels on the periphery⁶; the use of a round bur to create a 360° deep chamfer¹⁷; a butt joint on the occlusal aspect with bevels on interproximal, buccal, or lingual margins; and a 360° butt joint.¹⁸

One rationale for the placement of bevels on the finish line is to improve aesthetics by concealing the margin through the "contact lens" effect,¹⁹ which occurs when porcelain veneers are bonded in place. Margins on posterior restorations are virtually imperceptible at conversational distance, which makes aesthetic improvement

by beveling margins of questionable value. If a translucent material is placed at the margin of the restoration — even using a butt joint — it will be indistinguishable following adhesive luting (Figures 5 through 7).

It is believed that beveling the cavosurface margins allows improved marginal fit and decreased potential for microleakage to be achieved. An *in vitro* study on the marginal fit and microleakage of porcelain inlays with beveled or butt joint preparations demonstrated no significant differences, except for the period of fabrication.²⁰ Due to the delicacy of maintaining thin areas of material through all the processing phases, it took 50% longer to fabricate the inlays with beveled margins.

Thin areas of either composite or porcelain — particularly in regions with high occlusal stress — are more susceptible to fatigue and thus fracture.²¹ Due to the limited benefits and the potential complications associated with bevels, the authors believe it is prudent to place a circumferential butt joint as close to a 90° exit angle as possible (Figure 8).

Based on empirical data, the occlusal thickness of the restoration and in the isthmus is generally established at 1.5 mm in order to resist intraoral stresses.¹³ While it generally requires greater force to fracture thicker unsupported materials, this dynamic changes when the material is laminated or bonded to a substrate. Laminated structures, by definition, are a constant strain system,²² and when stress is applied, the material with the highest modulus of elasticity will absorb the majority of the stress. This explains the reason extremely thin restorations of porcelain bonded to enamel have performed well clinically. As the bonding substrate becomes more flexible,

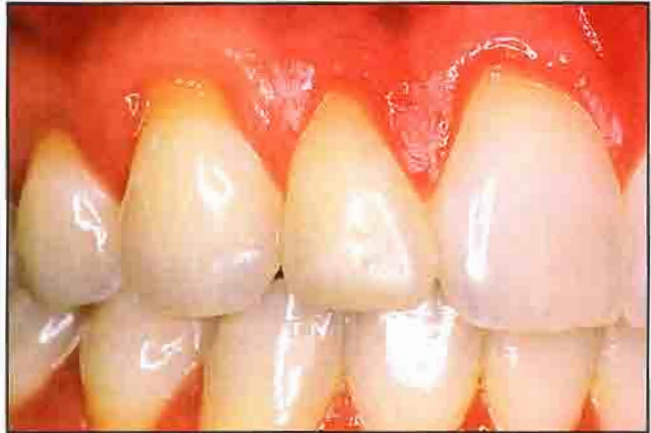

Figure 9. Preoperative buccal view of maxillary right lateral incisor (Courtesy: Michael Miller, DDS).

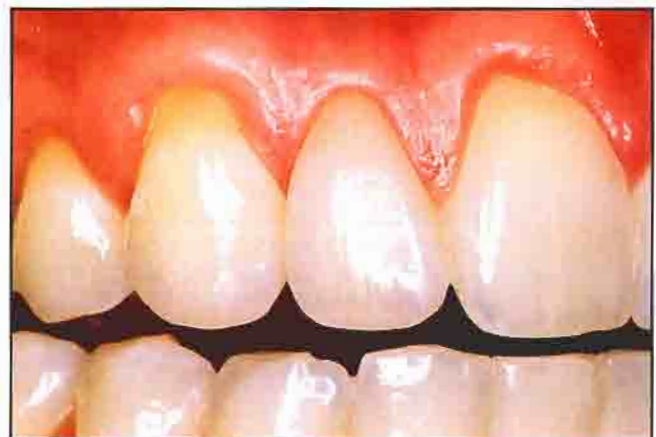

Figure 10. Postoperative buccal view of tooth #7, which has been restored with a second-generation composite veneer (Courtesy: Michael Miller, DDS).

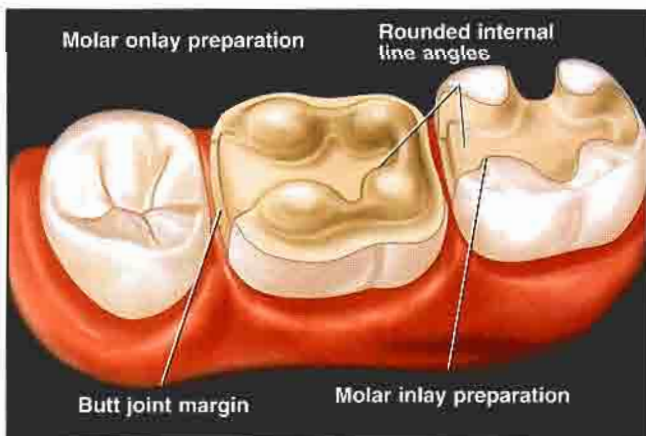


Figure 8. Diagram of preparations for inlay and onlay restorations demonstrates preparation design with butt joint (90°) finish lines.

as in dentin or a composite buildup, greater loading stress is concentrated in the bonded restoration, which makes it more susceptible to catastrophic failure. Thus, in teeth with minimal remaining enamel, large buildups, or thin teeth, support for the composite (eg, internally placed fibers) should be accomplished, since such fiber-reinforced crowns have demonstrated fracture strength similar to PFM crowns.²³

Although the literature indicates that bonded restorations strengthen teeth, the supporting research is at best equivocal,²⁴ and based on load to failure tests.^{25,26} Teeth are not loaded in this manner in the oral environment, where they are subjected to millions of cycles of subcritical loads. Thus, cyclic fatigue testing, with concomitant thermal cycling, is more clinically relevant. While initial cusp strengthening and reduced cusp flexure can be

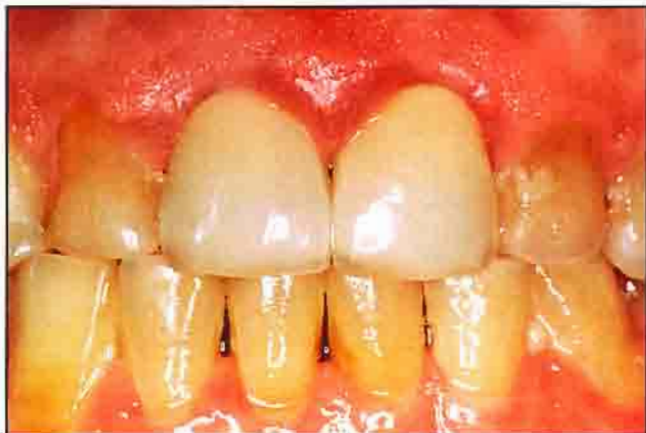

Figure 11. Preoperative facial view of patient who requires treatment with full-coverage crown restorations (Courtesy: Robert Rifkin, DDS).

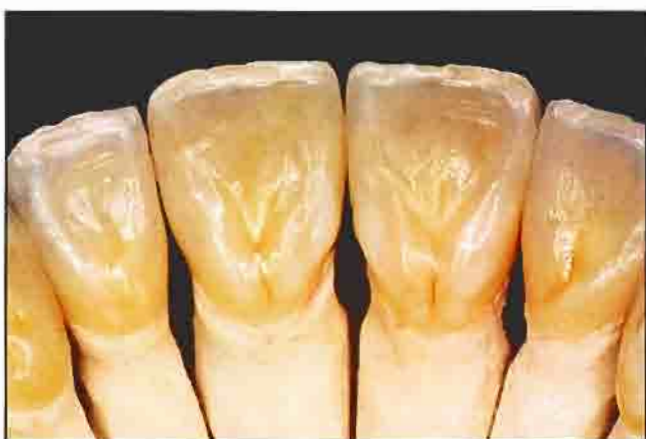

Figure 12. Fiber-reinforced crown restorations (belleGlass, Kerr/Sybron, Orange, CA) fabricated in the laboratory (Laboratory procedure: Vincent Devaud, MDT).

demonstrated, the long-term nature of this support has been questioned. One study of the long-term fatigue of teeth restored with MOD composite resins determined that tooth reinforcement was lost following loading cycles that were within the physiologic chewing range.²⁷ Since the long-term nature of cusp support for adhesively bonded restorations is relatively suspect, it would be prudent to onlay weak and undermined cusps.

In inlay restorations, bonding interfaces are primarily subjected to shear and tensile stresses when cusps are loaded, and under repeated cyclic loading fatigue, can ultimately fail. Consequently, one objective of a bonded restoration (ie, tooth reinforcement) would be lost. Teeth restored with an exaggerated taper of the occlusal isthmus (ie, thin and weakened cusps) demonstrated reduced fracture resistance in bonded restorations when

compared to teeth restored with a narrower isthmus preparation.²⁸ Therefore, onlaying weakened cusps would create a more favorable environment for force distribution, as the force on the bonding interface and cusp would generally be compressive in nature.

As a general guide, when the isthmus preparation exceeds one half of the distance from the central fossa to the cusp tip, onlaying the cusp should be considered. In areas of low stress, and where there is minimal potential of tooth flexure, thinner areas of tooth structure may be judiciously inlayed. As with inlays, onlay preparations should consist of a butt joint finish line and rounded internal line angles with slightly flared internal walls. For large restorations or weak teeth with minimal enamel, fibers should be included as a base on which to veneer the composite. The addition of fibers significantly increases the flexural strength and fracture resistance of the definitive restoration.⁹

One use of the new materials is for anterior veneer restorations (Figures 9 and 10). Due to the decreased potential for abrasion of the opposing dentition and excellent optical properties of the polymer- and resin-based materials, this may prove to be a useful clinical modality.

Crowns and Fixed Partial Dentures

The primary indication for the use of these materials is in crown applications when wear of the opposing dentition is of concern, although fiber-reinforced composite restorations can also be utilized when metal-based modalities are refused by patients, or in patients with allergies to alloys. One potential benefit of this class of materials is the ease of reparability, but no data yet exists to prove the reliability of such a repair.

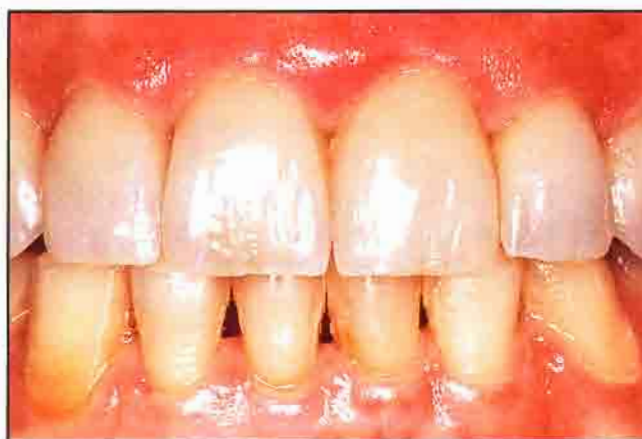

Figure 13. Postoperative facial view of the definitive full-coverage crown restorations (Courtesy: Robert Rifkin, DDS).

Several clinical case presentations that demonstrate the use of fibers as a framework for crown restorations and fixed partial dentures (FPD) have appeared in the literature.^{29,31} While no long- or even medium-term data have been reported on the clinical success of these materials for fiber-reinforced crowns and FPDs, one short-term report on 60 single-crown restorations has demonstrated no breakage at 1 year for the belleGlass material.¹² For full-crown applications, fiber reinforcement should be routinely accomplished to improve the physical properties (eg, fracture resistance) of the finished restoration (Figures 11 through 13). The majority of crown applications are performed on teeth that are structurally compromised with minimal or no remaining enamel. Thus, under load, the tooth is more likely to flex, which concentrates stress in the veneering crown. This effect would be mitigated by the addition of fibers.

Preparations for full-coverage crown restorations should follow the same guidelines utilized for all-ceramic crowns (Figure 14). Primarily, the finish line should be a butt joint with rounded internal line angles. Axial reduction on facial surfaces in the aesthetic zone should allow for 1.5 mm of crown thickness. Interproximal and lingual axial reduction of 1 mm is adequate, and a 1.5 mm to 2 mm reduction for occlusal or incisal areas allows optimal anatomic and optical form to be developed.

One principal use for fiber-reinforced composite materials is for conservative inlay FPDs, where a small inlay is prepared into an abutment tooth to be used as a retainer.^{29,30} While conservative removal of tooth structure is an important clinical objective, other factors (eg, stress type and distribution and bonding surface area) become more critical in FPD applications compared to single-tooth restorations (Leinfelder, personal communication). The more flexible a material is, the more it will bend under a given load. Fixed partial dentures with bonded attachments at both connectors would flex more than a similar metal-based restoration. Since the increased flexure concentrates greater stress on the cement interface (Leinfelder, personal communication), it is critical to provide adequate bond strength and surface area for the bonded interface in order to resist the shear and tensile forces applied to the area in function. While designing the preparation of an FPD, consideration must be given to the direction, type, and degree of the forces that will be applied to the restoration. As bonding surface area is minimal, only minute inlay preparations should be

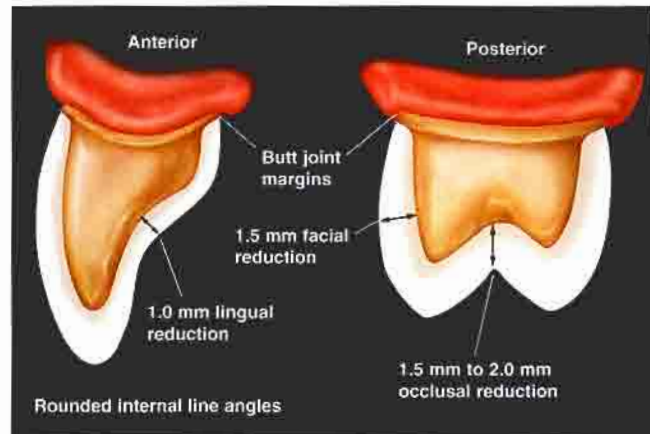


Figure 14. Diagram demonstrates recommended preparations for full-coverage crown restorations.

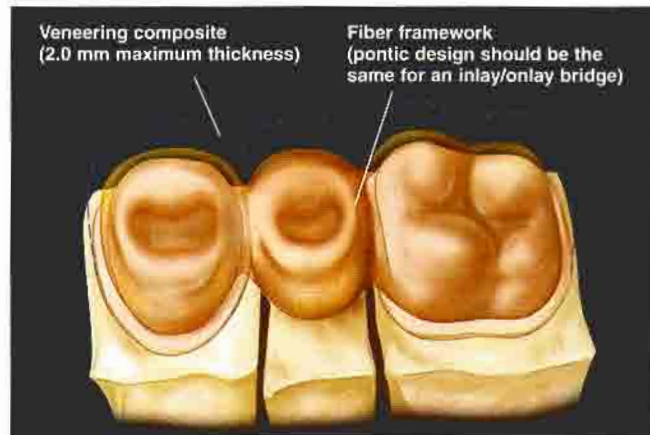


Figure 15. Diagram of fiber framework with optimal pontic and connector design that allows for proper support of the significantly weaker veneering material.

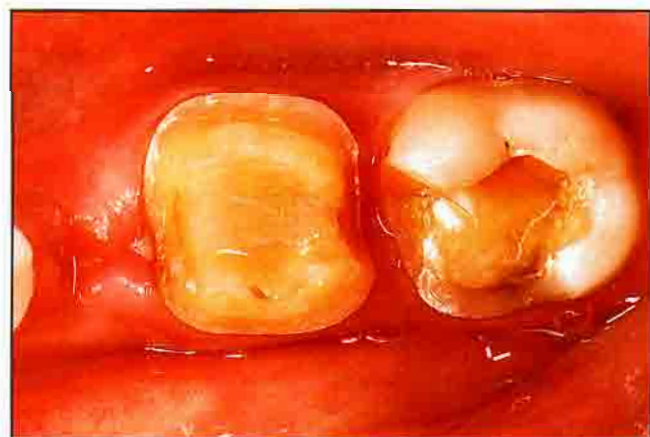

Figure 16. Occlusal view of tooth #19 prepared for an onlay restoration. Note that tooth #20 is missing.

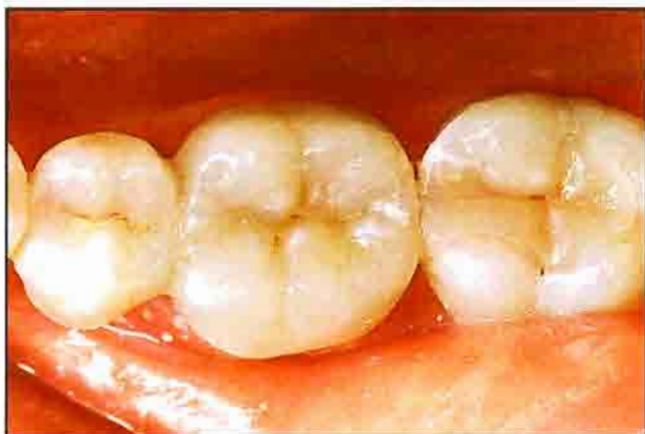

Figure 17. Postoperative view of cantilever FPD that replaces tooth #20. The adjacent tooth (#21), which did not require restoration, was undisturbed (Laboratory procedure: Vincent Devaud, MDT).

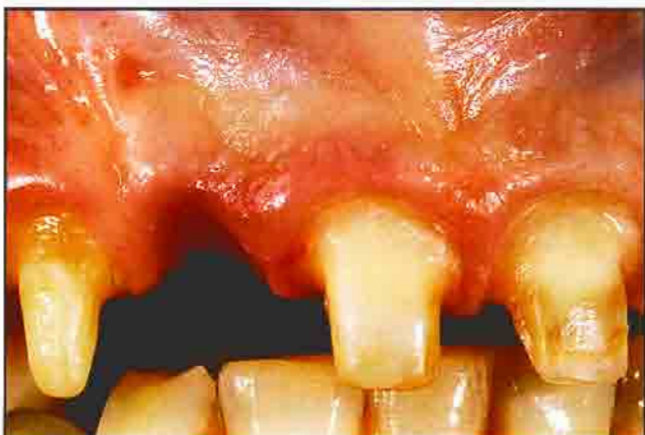

Figure 18. Facial view of preparations for composite resin-fused-to-metal crown restorations and fixed partial dentures.

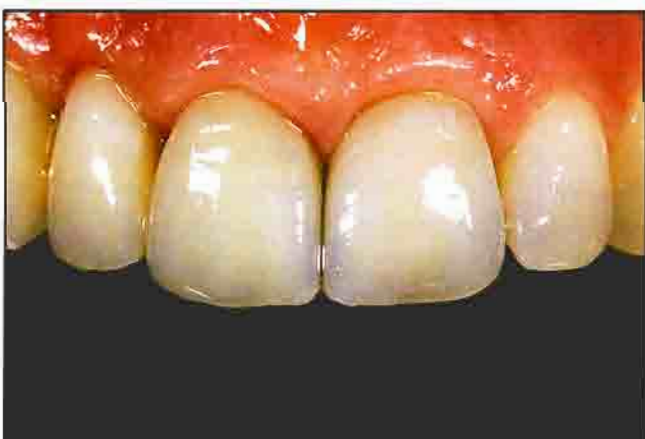

Figure 19. Postoperative facial view of composite resin-fused-to-metal frameworks on teeth #6 through #9 (Clinical and laboratory procedures: Edward A. McLaren, DDS).

considered to retain FPDs. Since long-term fatigue can jeopardize tooth reinforcement, it may be prudent to fully or partially onlay a cusp to increase the bonding surface area.

The pontic also warrants consideration in the design of the fiber framework, which must provide support for overlying composite material. As in metal-ceramic technology, the weak aspect of the fiber-based system is the veneering material. Large unsupported areas of the optimized composite are susceptible to fracture. Support should be provided for the veneering composite so that the design of the pontic framework mimics the shape of the finished tooth (Figure 15). The veneering composite on the completed pontic should have a maximum thickness of 2 mm.

Fixed partial denture applications, in which some form of retainer (Maryland-type wing, inlay, onlay, full-coverage) is prepared on both sides of the edentulous space, have been universally recommended. Due to the potential increase in stress on the bonding interface in the flexible materials, cement failure and microleakage may result in recurrent caries. If both teeth adjacent to the edentulous space do not require restoration, the use of a single-tooth cantilever restoration should be considered. Assuming a sound abutment exists, the principal considerations for the utilization of the cantilever prosthesis are the inherent physical properties of the material used, ie, that they are adequate to resist fracture. Two studies demonstrated flexural strengths of approximately 900 MPa for these fiber-reinforced materials, which is nearly twice the ultimate tensile strengths of the metals used for metal-ceramic restorations.^{4,7} In single-tooth cantilevers it is only necessary to fit one abutment, a larger connector can be fabricated, and stress is generally concentrated on the connector rather than on the cement seal. In addition, the cantilever design is regarded as conservative, since only one tooth requires preparation (Figures 16 and 17).

While onlay and possibly inlay FPDs are conservative applications for fiber-reinforced optimized composites, metal-reinforced optimized composite FPD applications should also be considered. Toxicity has been a concern with porcelain-fused-to-metal restorations; non-precious metals are typically added to metal-ceramic formulations to create a metal-oxide that chemically bonds to the porcelain. It is the oxide layer that easily corrodes and invests the surrounding tissues, which causes the

reaction. Compromised aesthetics also result from the "tattooing" of soft tissue and the lack of light propagation and opaqueness around dark metal margins. Alternative alloys that exhibit improved optical properties when used with metal-ceramic porcelains have recently been introduced.³³ Although these new alloys appear ideally suited for use with the optimized composite materials (Figures 18 through 20), it is important to note that no clinical data exist to support this application.

While fiber-reinforced frameworks veneered with porcelain have been utilized in Maryland FPDs,³¹ this application may cause unfavorable stress concentration in the porcelain laminate. In this instance, high-modulus and brittle porcelain is veneered onto lower modulus resin-infiltrated fiberglass or polyethylene fibers. If the applied force is sufficient to cause flexure of the fiber framework, stress will concentrate in the porcelain and result in potential failure. In order to benefit from the increased flexural strength of the framework, the veneering material should possess a similar flexural strength. Fiber frameworks should generally be veneered with optimized composite materials, which have demonstrated increased physical properties compared to conventional porcelains.

Implant-Supported Restorations

In the authors' opinion, one of the primary indications for optimized composites is in implant-supported restorations, particularly those with metal substructures (Figures 21 through 23). Design parameters for implant-supported fixed restorations have mandated the use of a screw-retained prosthesis or a cement-retained prosthesis that is temporarily cemented to facilitate retrieval. The ability to remove the restoration allows improved access for hygiene and serviceability of the prosthesis and the implants.

For a large metal-ceramic prosthesis, or one that will be removed periodically, the risk of fracture is high. Larger prostheses generally endure more porcelain firings and postceramic soldering, which increases the residual stresses in the restoration and its potential for failure in function. Due to inherent difficulties (microflaws, blistering, cracking, refiring) with metal-ceramic technology, the reparation of a fractured prosthesis is extremely difficult. Thus, recommendations for reparation have generally advocated the use of silane with composite resin, so as not to refire the porcelain.

One potential solution is to use an optimized composite metal-supported prosthesis, since frameworks can be fit and presoldered if necessary, and the application

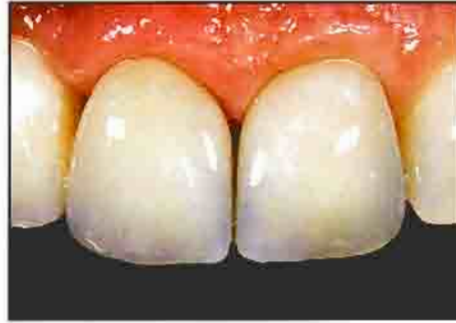

Figure 20. Magnified postoperative view of the definitive restorations. Note the enhanced aesthetics achieved with the indirect technique.



Figure 21. Facial view of type-4 cast-gold framework that incorporates bead retention for the veneering material.

of the veneering composite will not warp the framework. The enhanced physical properties of the optimized composite materials also increase the fracture resistance of the prosthesis. Should fracture occur, the restoration is easily repaired with the same material. The design of the framework should allow mechanical retention to be placed on the surface of the framework by the incorporation of glass beads on the waxup prior to casting (Figure 21). Relying only on chemical bonding by various silane systems has been problematic, with the potential for hydrolysis of that bond and delamination of the veneering material. It should be noted that no reported data yet exist on the success of procedures that feature optimized composite resin in conjunction with implant-supported restorations.

Cement Considerations

While optimized composite materials have improved physical properties relative to conventional ceramics, they are low compared to casting alloys. Consequently, this class of materials should always be adhesively luted to increase their resistance to fracture.³⁴ The addition of

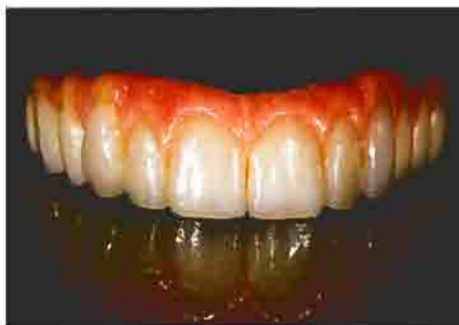

Figure 22. Composite resin was veneered over the metal framework during the fabrication of the implant-supported FPD.

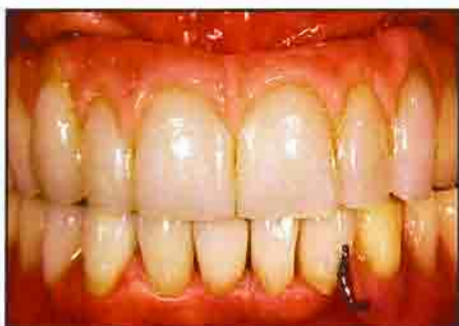

Figure 23. Postoperative facial view of the implant-supported FPD (Clinical and laboratory procedures: Edward A. McLaren, DDS).

fibers to the restoration significantly increases the fracture strength, but no data exist as to whether this is adequate for conventional cementation. Since increased retention, decreased microleakage, and decreased fracture potential can be achieved with adhesive procedures, even fiber-reinforced restorations should be luted accordingly.

One limitation of laboratory-processed composite resins is the lack of unsaturated double bonds available for chemical bonding. In addition, it is difficult to effectively etch the extremely fine particle size of the filler material, which leaves a questionable surface for micro-mechanical adhesion to the composite luting resin. The average filler particle size of one optimized composite resin (belleGlass, Kerr/Sybron, Orange, CA) is 10 μm , which reduces polymerization shrinkage. This material also demonstrates decreased microleakage and has a coefficient of thermal expansion comparable to that of natural tooth structure.³⁵ Analysis of the material's sand-blasted surface with a scanning electron microscope (SEM) indicates that it is very similar in nature to hydrofluoric acid etched porcelain, which should promote increased adhesion.

The composite luting cement should be dual-cured (eg, Nexus, Kerr/Sybron, Orange, CA) as light-cured cements will not be polymerized to a sufficient depth (2 mm).³⁵ Since dual-cure cements cure to varying levels,³⁶ it is essential to select a suitable cement for use with optimized composite resins.

In order to reduce the potential of subsequent breakdown,^{37,38} the marginal fit of the adhesively luted restorations should be a maximum of 100 μm .³⁸ Since polymerization of the cement causes micromovement of the restorations, it is critical to avoid an excessively tight fit as well. Consequently, the margins should fit passively to allow for this potential micromovement.

Complete removal of all temporary cement and any potential contaminants on the tooth surfaces is recommended to promote maximum adhesion. Since the total-etch technique apparently neutralizes any effect residual eugenol may have on the setting of resin cements,³⁹ eugenol-based temporary cements may be utilized in these procedures. Prior to cementation, the teeth can be abraded (Microetcher II, Danville Engineering, San Ramon, CA) with aluminum particles to remove residual temporary cement and to improve retention. Rubber dam isolation is highly recommended during total-etch and bonding procedures.

The removal of excess cement can be time consuming and difficult, particularly for inlays and onlays. This objective can be achieved by waxing the margin region on the nonbonded areas of the inlay/onlay restoration. Care must be taken to prevent the wax from contacting the internal surface, as it will affect seating. Once the wax is placed on the marginal area, the restoration is resealed on the tooth to verify that it does not inhibit seating. As the luting procedures are completed as previously described, the excess cement will flow up onto the wax. Once the cement is set, the wax and any residual cement is easily removed from the restoration. Thus, no adjustment of the restoration is necessary except for occlusion. Since excess cement can be clearly visualized in contrast to the wax and removed prior to setting, minimal removal is necessary on the tooth itself. In all-ceramic crown restorations with full-porcelain occlusal surfaces, the authors have experienced instances of fracture upon cementation. This can be presumably attributed to a point load that was generated by the patient biting on an orangewood stick. Since this could occur with full composite occlusal surfaces as well, it may be advisable to make an impression of the occlusal surface of the restoration prior to cementation. This putty

impression is placed on the occlusal surface onto which the orangewood stick is positioned for the patient's bite. This will spread the biting force evenly over the occlusal surface and minimize the potential for fracture.

Conclusion

Treatment planning with any restorative material involves the consideration of several important criteria, not the least of which are the mechanical stresses it withstands in the oral environment. Since these materials are subjected to a myriad of chemical and physical forces intraorally, the clinician must have a basic understanding of the structural elements of a material and its inherent physical properties in order to more effectively predict its performance.

Previous materials with inadequate physical and chemical properties have resulted in clinical failure rates that are unacceptable. The development of second-generation laboratory-processed composites has significantly improved the physical and aesthetic properties of existing materials due to the heat and pressure curing utilized in their fabrication. As a result of their enhanced physical properties and ease of use, these materials appear to be ideally suited for inlay and onlay applications. Several innovative applications of these materials have been presented in this article, which has also discussed the considerations of the use of these new composite materials with the use of fiber and metal reinforcement.

Acknowledgment

The authors mention their gratitude to Joe Weisz, CDT, for the fabrication of the implant framework demonstrated in this article.

References

1. American Dental Association Survey Center. 1990 Survey of Dental Restorations. In: Survey of Dental Services, 1990. Chicago: ADA Survey Center
2. Touati B. The evolution of aesthetic restorative materials for inlays and onlays: A review. *Pract Periodont Aesthet Dent* 1996;8(7):657-666.
3. Leinfelder KF. New developments in resin restorative systems. *J Am Dent Assoc* 1997;128(5):573-581.
4. Ceramic-Polymer Crowns and Fixed Prostheses: CRA Newsletter, 1997;21(5).
5. Miara P. Aesthetic guidelines for second-generation indirect inlay and onlay composite restorations. *Pract Periodont Aesthet Dent* 1998;10(4):423-431.
6. Dyer SR, Sorensen JA. Flexural strength and fracture toughness of fixed prosthodontic resin composites. *J Dent Res* 1998;77(special issue):160(abstract No. 434).
7. Freilich MA, Karmaker SC, Burstone CJ, Goldberg AJ. Flexural strength of fiber-reinforced composites designed for prosthodontic application. *J Dent Res* 1997;76(special issue):138(abstract No. 999).
8. Bennett ME, Puckett AD, Parsell DE, Roberts SB. Conversion of heat and pressure cured composite. *J Dent Res* 1996;75(special issue):291(abstract No. 2188).

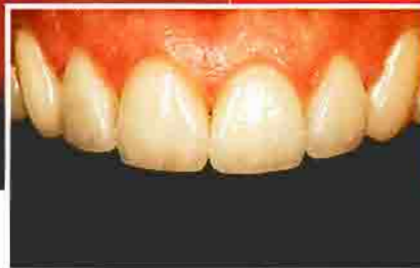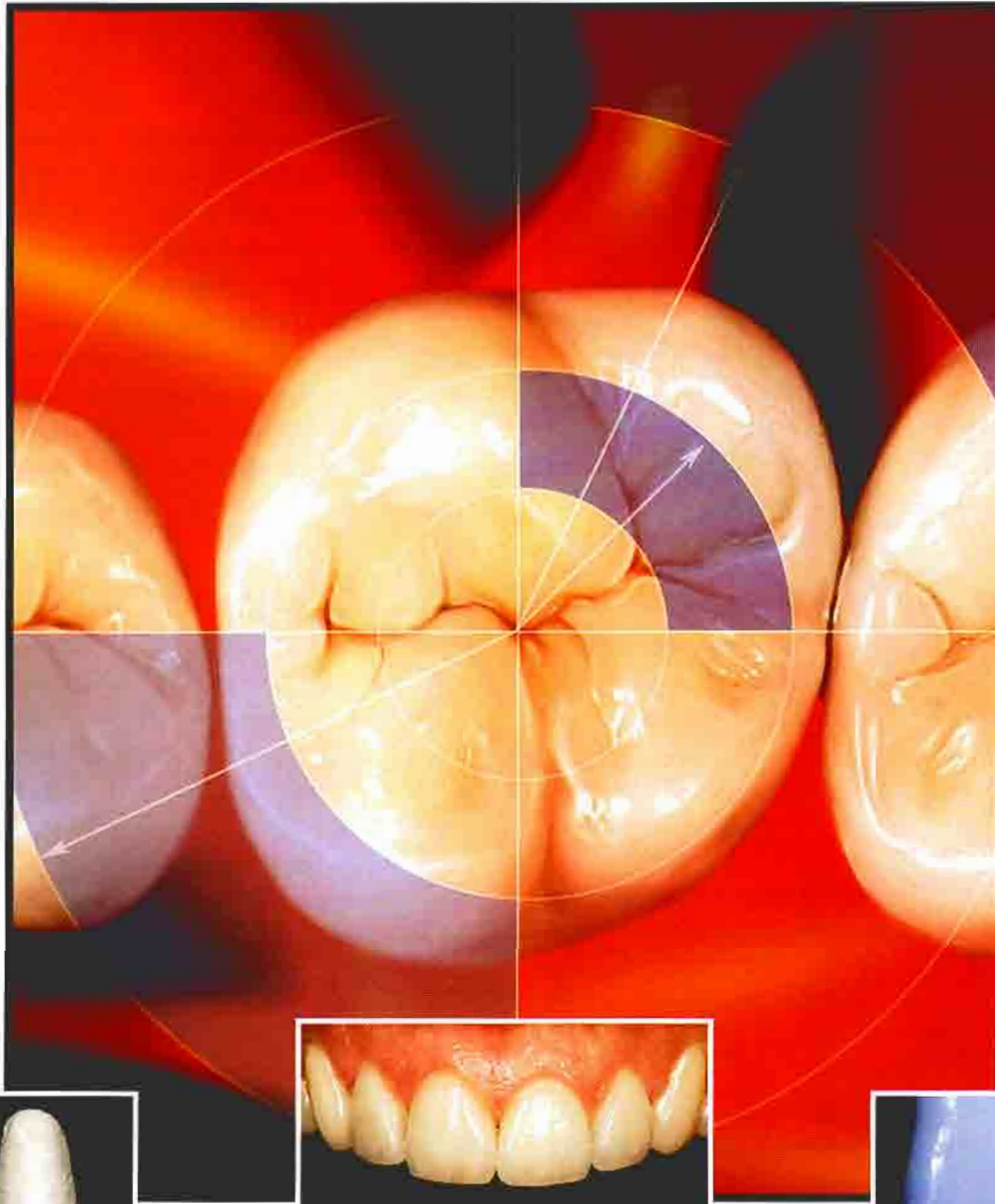
9. Sorensen JA, Dyer SR, Condon JR, Ferracane JL. In vitro wear measurements of fixed prosthodontic composite systems. *J Dent Res* 1998;77(special issue):160(abstract No. 432).
10. Leinfelder KF. A conservative approach to placing posterior composite resin restorations. *J Am Dent Assoc* 1996;127(6):743-748.
11. Dietschi D, Spreafico R. Current clinical concepts for adhesive cementation of tooth-colored posterior restorations. *Pract Periodont Aesthet Dent* 1998;10(1):47-54.
12. van Dijken JW. A 6-year evaluation of a direct composite resin inlay/onlay system and glass ionomer cement-composite resin sandwich restorations. *Acta Odontol Scand* 1994;52(6):368-376.
13. Christensen R, Christensen G, Vogl S, Bangertner V. A 2-year clinical comparison of six inlay systems. *J Dent Res* 1991;70(special issue):561(abstract No. 2360).
14. O'Neal SJ, Leinfelder KF, Wright W, Gerbo LG. Clinical evaluation of two types of composite resin inlay systems. *J Dent Res* 1991;70(special issue):457(abstract No. 1527).
15. Roulet JF, Degrange M. Inlay restorations. *J Calif Dent Assoc* 1996;24(9):48-62.
16. Rifkin LR. Maxillary reconstruction utilizing a second-generation glass-reinforced resin material. *Pract Periodont Aesthet Dent* 1998;10(2)(suppl 2):1-7.
17. Garber DA, Goldstein RE. Porcelain and Composite Inlays and Onlays: Esthetic Posterior Restorations. Carol Stream, IL: Quintessence Publishing Co., 1994.
18. Jackson RD. Aesthetic inlays and onlays: A clinical technique update. *Pract Periodont Aesthet Dent* 1993;5(3):18-26.
19. Materdomini D, Friedman MJ. The contact lens effect: Enhancing porcelain veneer esthetics. *J Esthet Dent* 1995;7(3):99-103.
20. Sorensen JA, McLaren EA, Avera S. Microleakage of MOD porcelain inlays with beveled margins vs butt joint margins. *J Dent Res* 1990;69(special issue):123(abstract No. 117).
21. Dietschi D, Spreafico R. Adhesive Metal-Free Restorations: Current Concepts for the Esthetic Treatment of Posterior Teeth (B3288). Chicago, IL: Quintessence Publishing; 1997:79-99.
22. McLean JW. Long term esthetic dentistry. Presented at the Newport Harbor Academy of Dentistry, Newport Beach, California, May 23, 1993.
23. Munoz CA, Torres J, Kobashigawa A, Shellard E. Effect of fiber reinforcement on the breaking strength of crowns. *J Dent Res* 1998;77(special issue):779(abstract No. 1177).
24. Donovan TE, Cho GC. Materials for conservative posterior restorations. *J Calif Dent Assoc* 1996;24(9):32-38.
25. Morin D, DeLong R, Douglas WH. Cusp reinforcement by the acid-etch technique. *J Dent Res* 1981;63(8):1075-1078.
26. Jaynt RB, Wiecekzowski G, Klockowski R, Davis EL. Effects of composite restorations on resistance to cuspal fracture in posterior teeth. *J Prosthet Dent* 1987;57:431-435.
27. Fissore B, Nicholls JL, Yuodelis RA. Load fatigue of teeth restored by a dentin bonding agent and a posterior composite resin. *J Prosthet Dent* 1991;65(1):80-85.
28. Burke FJ, Wilson NH, Watts DC. Effect of cavity wall taper on fracture resistance of teeth restored with resin composite inlays. *Oper Dent* 1993;18(6):230-236.
29. Dickerson WG, Rinaldi P. The fiber-reinforced inlay-supported indirect composite bridge. *Pract Periodont Aesthet Dent* 1996;8(suppl):1-6.
30. Nixon RL. The advent of metal-free dentistry: A versatile new fiber and polymer-glass system. *Pract Periodont Aesthet Dent* 1997;9(suppl):1-6.
31. Feinman RA, Smidt A. A combination porcelain/fiber-reinforced composite bridge: A case report. *Pract Periodont Aesthet Dent* 1997;9(8):925-929.
32. Filled Polymer Crowns: 1 and 2 Year Status Report. CRA Newsletter 1998;22(10):1-3.
33. Shaher I, Whiteman A. Captek: A new capillary casting technology for ceramometal restorations. *GDT* 1995;18:9-20.
34. Rosenstiel SF, Gupta PK, Van der Sluys RA, Zimmerman MH. Strength of a dental glass-ceramic after surface coating. *Dent Mater* 1993;9(4):274-279.
35. Kobashigawa A, Shellard E. Microleakage of low thermal expansion indirect composite resin restorations. *J Dent Res* 1998;77:938(abstract No. 2451).
36. El-Badrawy WA, El-Mowafy OM. Chemical versus dual curing of resin inlay cements. *J Prosthet Dent* 1995;73:515-524.
37. Dietschi D, Spreafico R. Adhesive Metal-Free Restorations: Current Concepts for the Esthetic Treatment of Posterior Teeth (B3288). Chicago, IL: Quintessence Publishing; 1997:185.
38. Suzuki S, Leinfelder KF, Shinkal K. Wear resistance of resin cements. *Am J Dent* 1995;8(2):83-87.
39. Tjan AH, Nemetz H. Effect of eugenol-containing endodontic sealer on retention of prefabricated posts luted with adhesive composite resin cement. *Quint Int* 1992;23(12):839-844.

PPAD

Practical Periodontics & AESTHETIC DENTISTRY

VOLUME 11 NO. 4

MAY 1999



CONSIDERATIONS IN THE USE OF POLYMER AND
FIBER-BASED INDIRECT RESTORATIVE MATERIALS

